Sex Estimation Using Pubic Bone Morphology in a Modern South African Sample: A Test of the Klales *et al.* Method

Michael W. Kenyhercz, MS
Department of Anthropology, University of Alaska Fairbanks, 310 Eielson Building, PO Box 757720 Fairbanks, AK 99775

Introduction

Sex estimation is an essential component of biological profile estimation during bio-archaeological and forensic identification of unknown skeletons. Due to females' ability for childbirth, the innominate has been a key area for evaluating and measuring sexual dimorphism. Phenice (1969) identified three key features that successfully determined if an individual was male or female with 96% accuracy: ventral arc, subpubic concavity, and the medial aspect of the ischio-pubic ramus.

Recently, Klales *et al.* (*in review*) have expanded the three dichtomous traits originally described by Phenice (1969) to an ordinal scale showing five possible scores that represent the possible range of variation in trait expression (Figure 1). Klales *et al*. (*in review*) scored a total of 210 left innominates from two different collections; 83 females and 87 males from the Hamann-Todd Osteological Collection at the Cleveland Museum of Natural History and 54 females and 86 males from the Bass Donated Skeletal Collection at the University of Tennesee, Knoxville. Klales *et al.* (*in review*) utilized linear discriminant function analysis, quadratic discriminant function analysis, k-nearest neighbor, kernal density probability and ordinal linear regression to examine sexual differences and achieved combined, cross-validated accuracies ranging from 85-94%.

Within forensic anthropology, there has been a concentrated focus to test the validity of commonly employed methods in response to the the *Daubert* rulings (1993) and, more recently, the 2009 report by the National Research Council. This present research was conducted to test the utility of the Klales *et al.* method on an independent, modern, and documented skeletal collection, as well as to supply researchers in South Africa with a population specific method for sex estimation from the innominate.

Materials

One-hundred and five (61 males and 44 females) left innominates from the Pretoria Bone Collection were scored in accordance to the illustrations and descriptions provided by Klales *et al*. (*in review*). The Pretoria Bone Collection is housed in the Department of Anatomy at the University of Pretoria in Pretoria, South Africa. The acquisition of skeletal material began in 1942 with the opening of the Department of Anatomy and the Medical School at the university (L'Abbe *et al.* 2004). In 1987, the skeletal material was reorganized into an accessible collection and is now a well-documented research resource. All skeletons are of known age, sex and self-assigned population group (2004). The skeletal material comes from donors and unclaimed remains with known biological demographic data from local hospitals in the Gauteng Province. Thus, the Pretoria Bone collection provides a good representative of modern South African groups (2004).

Methods

From the original methods employed by Klales *et al*. (in review) this study included: linear discriminant function analysis (LDA), quadratic discriminant function analysis (QDA), k-nearest neighbor to three neighbors (kNN), and ordinal logistic regression (LR). Additionally, naïve Bayesian (NB) and random forest (RF) models were used to further analyze the degree of sexual dimorphism in the sample. Traits for each specimen were scored according to the illustrations (Figure 1) and corresponding descriptions provided Klales *et al*. (*in review)*:

Subpubic Contour (SPC)

1. Well-developed concavity present inferior to symphyseal face and along length of inferior ramus
2. Slight concavity present inferior to face extended partially down inferior ramus
3. No concavity present, bone is nearly straight (may be a very slight indentation just below the symphyseal face)
4. Small convexity, especially pronounced along inferior pubic ramus
5. Large convexity, especially pronounced along inferior pubic ramus

Medial Aspect of the Ischio-Pubic Ramus (MIPR)

1. Ascending ramus is narrow dorso-ventrally with a sharp ridge of bone present below the symphyseal face
2. Ascending ramus is narrow dorso-ventrally with a plateau/rounded ridge of bone present below the symphyseal face
3. Ascending ramus is narrow dorso-ventrally with no ridge present
4. Ascending ramus is medium width dorso-ventrally with no ridge present
5. Ascending ramus is very broad dorso-ventrally with no ridge present

Ventral Arc (VA)

1. Arc present at approximately or at least a 40° angle in relation to the symphyseal face with a large triangular portion of bone inferiorly placed to arc
2. Arc present at approximately a 25-40° angle in relation to the symphyseal face with a small triangular portion of bone inferiorly placed to arc
3. Arc present at a slight angle (less than 25°) to the symphyseal face with a slight, nontriangular portion of bone inferiorly placed to arc
4. Arc present approximately parallel to the symphyseal face with hardly any additional bone present inferior to arc
5. No arc present (therefore, no additional bone present inferior to the arc)

Results

The classification accuracies ranged from 90.6% to 99.2% depending on the analysis. The percent correct classifications are listed below in Table 1. Figure 2 represents an extremely feminine female and Figure 3 represents an extremely masculine male in the South African sample.

Table 1. Percent correct classifications using each statistical method. Each discriminant function used leave-one-out crossvalidation. The kNN was to the third neighbor. The naïve Bayesian used 1/5th of the sample as a training model. The random forest model consisted of 1000 trees, where one of the three variables, or a combination of any of the three could be used at each decision split.

Method	Female %	Male %	Combined%
LDA	95.5	95.1	95.2
QDA	95.5	98.4	97.1
kNN	90.9	90.2	90.6
LR	100	98.4	99.2
NB	95.5	96.7	96.2
RF	97.7	95.1	96.2

Discussion

The results show, with the exception of the kNN, that classification was higher for each analysis than those of the original study. Contrary to Klales *et al*., the ventral arc was shown to be the most important trait in sex estimation followed by subpubic concavity, and then the medial aspect of the ischio-pubic ramus. The order of importance of each trait was consistent in the weights of the both discriminant functions, and the importance in the random forest model. The males show a greater range of variation in each trait expression compared to the females. The greater classification accuracies from the study indicate that there is greater sexual dimorphism in the pelvis in this sample than in the samples the study was based upon.

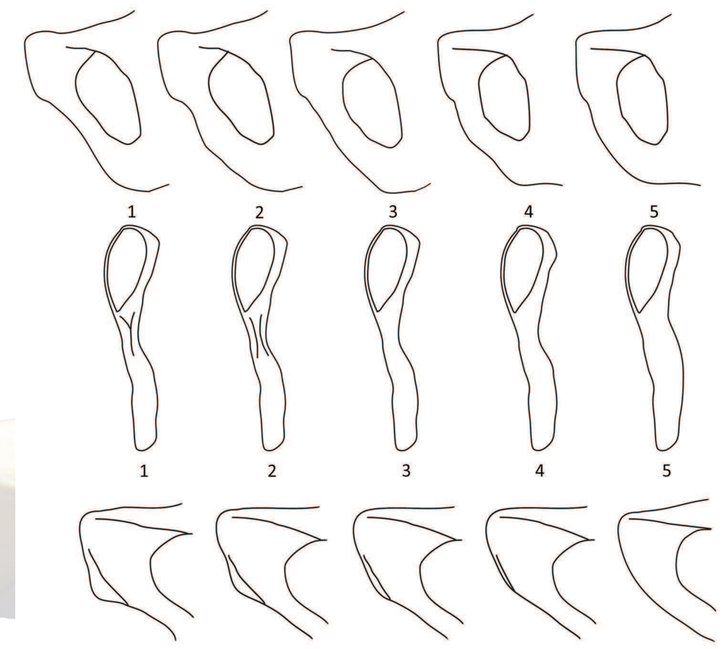

Figure 1. Illustrations from Klales et al. (in review). See corresponding descriptions.

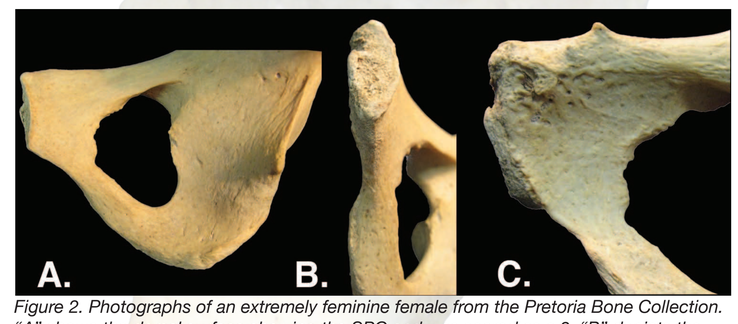

Figure 2. Photographs of an extremely feminine female from the Pretoria Bone Collection. "A" shows the dorsal surface showing the SPC and was scored as a 2. "B" depicts the MIPR viewed inferolaterally and was scored as a one, notice the sharp ridge of bone inferior to the symphyseal face. "C" shows the ventral arc on the ventral surface and was scored as a 1 based on the arc in relation to the symphyseal surface. Photographs courtesy of Univeristy of Pretoria, Department of Anatomy, taken by Kyra Stull.

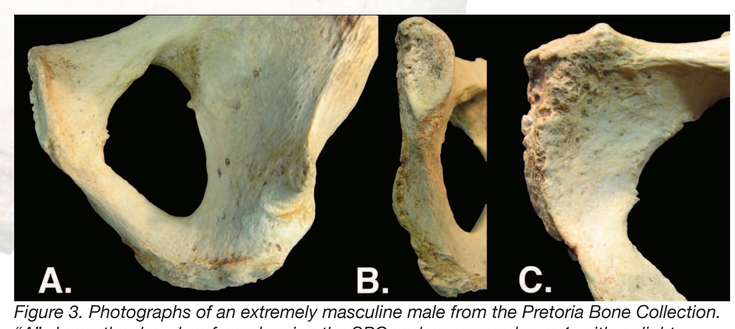

Figure 3. Photographs of an extremely masculine male from the Pretoria Bone Collection. "A" shows the dorsal surface showing the SPC and was scored as a 4, with a slight convexity on the ramus inferior to the symphyseal face. "B" represents the MIPR viewed inferolaterally and was scored as a 4. "C" shows a slight arc that is approximately parallel to the symphyseal face on the ventral surface and was scored as a 4. Photographs courtesy of Univeristy of Pretoria, Department of Anatomy, taken by Kyra Stull.

Conclusions

The Klales *et al.* method proved to be successful when applied to a modern South African sample, even more so than the original study. This research indicates that this improvement of the Phenice method can be confidently applied to a South African population.

Acknowledgements

I would like to thank Alexandra Klales for an advanced copy of the manuscript and illustrations for this study, as well as editorial comments along the way. Additionally, I would like to thank Dr. Ericka L'Abbe and Marius Loots for access to the Pretoria Bone Collection and help with navigating the sample. I would like to thank Kyra Stull for taking the photographs above. Lastly, I would like to thank Jolandie Myburgh for help with the collection and toting me around the entirety of South Africa.

References

Daubert v. Merrell Dow Pharmaceuticals. 1993. US Supreme Court *509.U.S.579,113S.Ct.2786, 125L. Ed.2d 469*.

Klales AR, Ousley SD, and Vollner JM. (in review). A revised method of sexing the human innominate using Phenice's nonmetric traits and statistical methods. *Am J Phys Anthropol*

L'Abbe EN, Loots M, and Meiring JH. 2004. The Pretoria bone collection: a modern South African skeletal sample. *Homo* 56:197-205.

National Academy of Sciences. 2009. Strengthening Forensic Sciences in the United States: A Path Forward. Washington, DC: The National Academies Press.

Phenice TW. 1969. A newly developed visual method for sexing the os pubis. *Am J Phys Anthropol* 30:297-302.